



# Case Report: Vertebral Artery Dissection Following Cervical Manipulation in the Setting of Prior Amphetamine Use



Stephanie Wang OMS-3<sup>1</sup>, Stephie Thomas OMS-3<sup>1</sup>, Anastasia Shikula-Smith DO<sup>1</sup>, Nabin Adhikari<sup>2</sup>, Brian Zylinski DO<sup>3</sup>  
Mohawk Valley Health System, Department of Hospital Medicine

## Introduction

Vertebral artery dissection (VAD) is a type of cervical artery dissection, accounting for about 2% of all ischemic strokes with the highest prevalence in 30-45 year old adults (10-25%). VAD presentation ranges from asymptomatic to a fulminant stroke, as dissection is possible at any point along the artery. VAD can either be spontaneous or traumatic. Examples of spontaneous causes include issues with vasculature such as connective tissue disorders or fibromuscular dysplasia and traumatic causes include blunt trauma and can also occur with forceful activities like vomiting and cervical spine manipulation. History of amphetamine abuse may be a contributing factor as well because amphetamines are known to have effects on the vascular system, including but not limited to vasculitis and vasospasm. Aorta, coronary artery, and internal carotid artery dissection has been reported in relation to amphetamine abuse.

## Case Presentation

A 30-year-old female presented in the ED with dizziness, abnormal gait, and headache. She had been experiencing headaches and ear discomfort for the past 2 months and was previously treated at an urgent care with prednisone, OTC analgesics, and warm compresses with no improvement. Several days before, she had cervical manipulation done by a chiropractor for headaches. She felt fine after leaving the chiropractor's office and had been nauseous ever since. The patient woke up dizzy and she felt like she was in a fog with confusion. She also reported decreased concentration and a dissociated state.

On physical exam, she was ill-appearing with chills, diaphoresis, and fatigue, but alert and oriented to person, place, and time with a Glasgow coma scale score of 15. She had trouble swallowing and voice changes. She endorsed blurry vision, but denied tremors, chest pain, shortness of breath, loss of consciousness, and back pain.

She had a positive Romberg sign with unsteady gait leaning to left. Finger-to-nose and heel-to-shin tests were normal. She described a new onset of numbness in both upper extremities. All deep tendon reflexes were intact except the left Achilles reflex of 1/4. Nystagmus were present with left eye ptosis. She did not present with tremors or syncope. Amphetamine abuse in remission for the past 8 years.

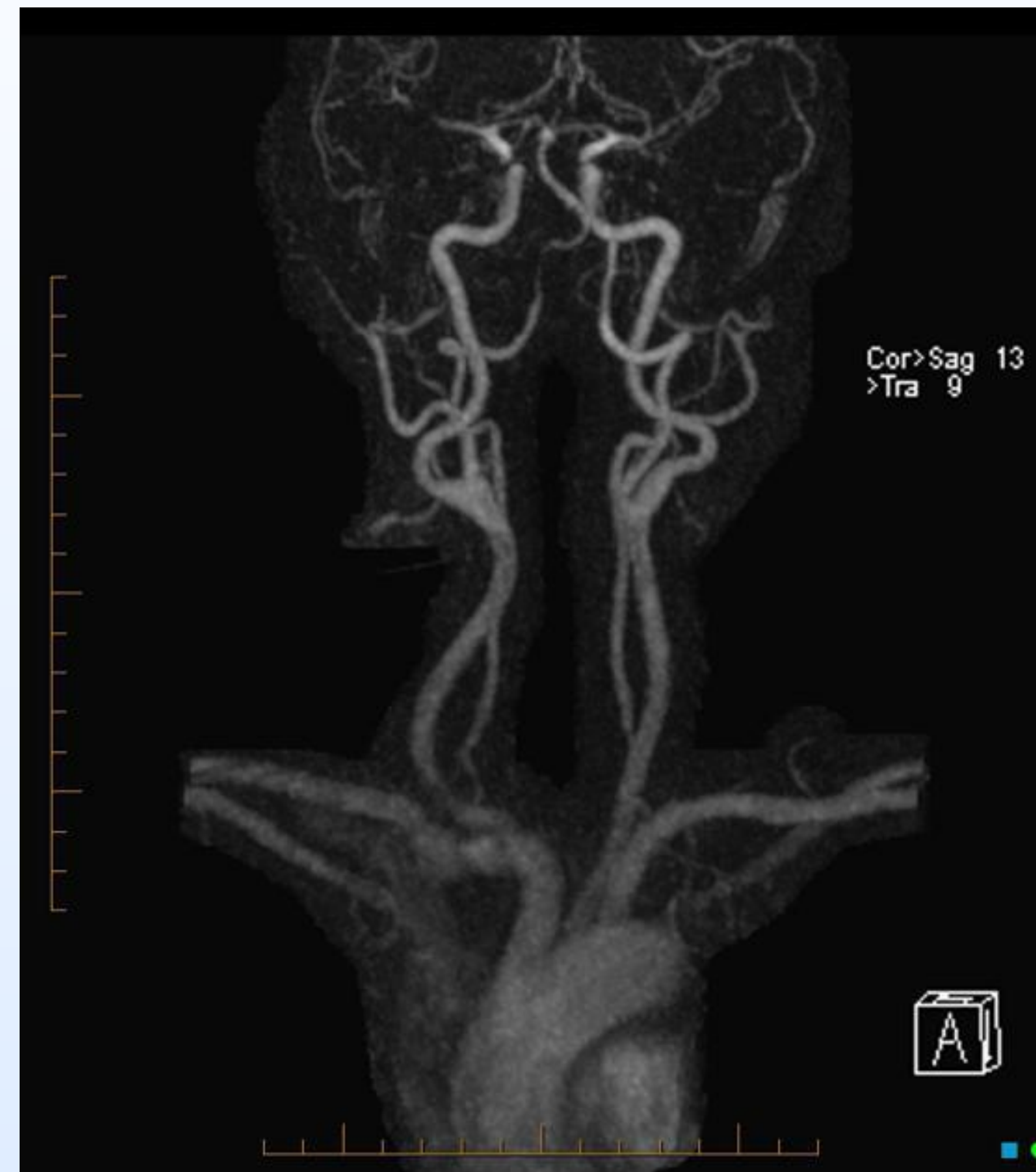

Figure 1. Right Vertebral Artery Dissection, MRA (Example Imaging)

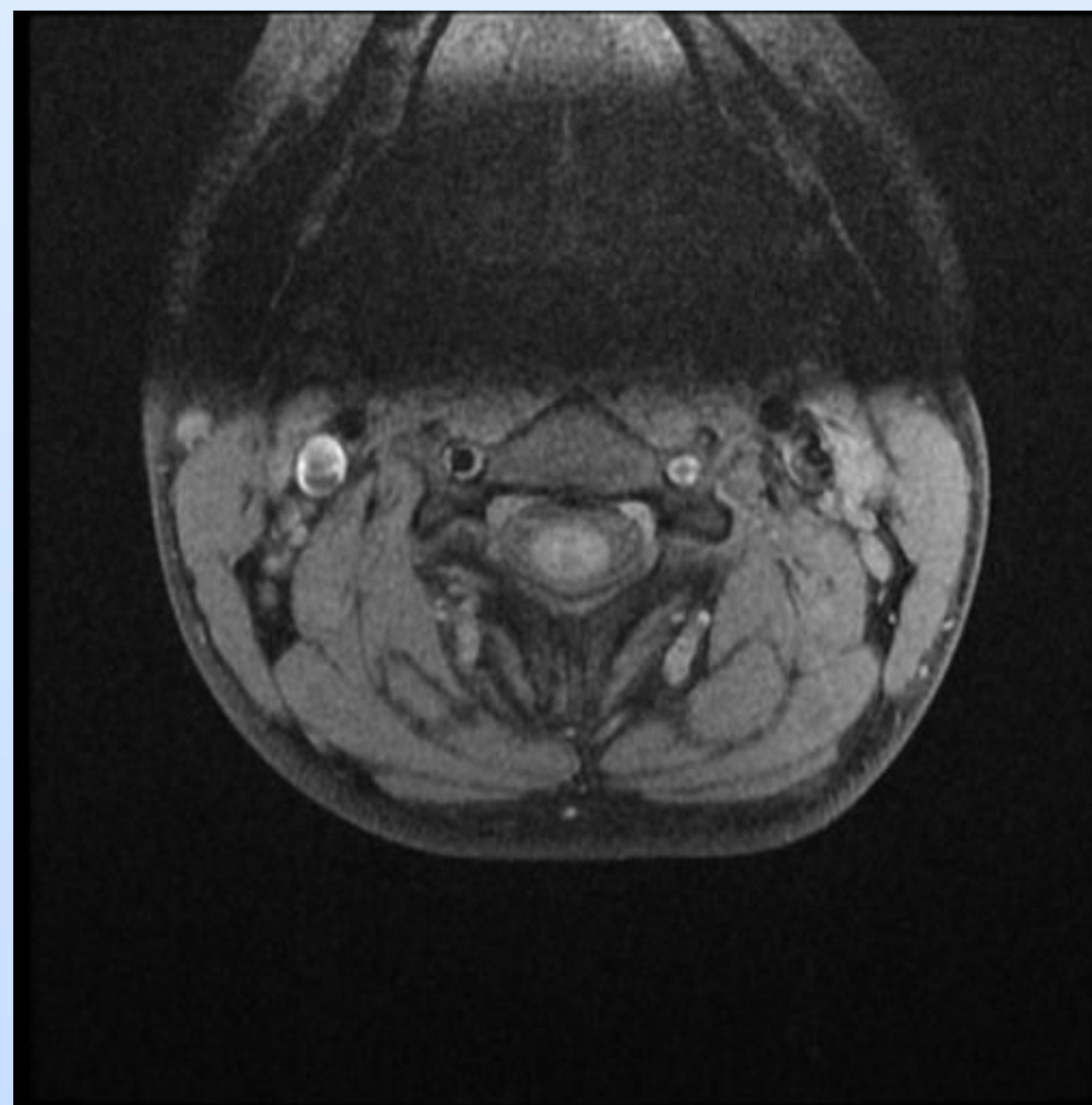


Figure 2. Left Vertebral Artery Dissection, Axial T1 (Example Imaging)

## Workup

- Due to her presentation, she was put under stroke protocol in the hospital. CT head without IV contrast showed no hemorrhage, mass, edema, or other significant acute findings.
- CT angiography of the head and neck showed a left vertebral artery dissection.
- MRI of the brain showed a small left lateral medullary cerebral vascular accident. Neurocritical care was consulted and determined that her medullary stroke and left vertebral artery dissection were caused by cervical spine manipulation.
- She was discharged with aspirin and clopidogrel, advised to not receive cervical spine manipulation in the future, and to follow-up with the outpatient neurological endovascular office.

## Discussion and Conclusion

- VAD is a leading cause of ischemic stroke in young adults and may occur spontaneously or after minor cervical trauma, including chiropractic and osteopathic cervical spine manipulation.
- The close temporal relationship between this patient's cervical manipulation and the onset of neurologic symptoms strongly suggests manipulation-induced left vertebral artery dissection resulting in a lateral medullary infarction.
- History of amphetamine use can be a contributing factor as it can cause vasospasms. Early vascular imaging and initiation of anti-thrombotic therapy are critical to optimizing neurologic outcomes.
- This case reinforces the importance of counseling patients with a history of cervical artery dissection to proceed with caution for future cervical spine manipulation, especially high velocity maneuvers, due to the potential risk of recurrence.

## Reference

- Figure 1: <https://radiopaedia.org/cases/terminal-right-vertebral-artery-dissection-post-neck-manipulation#image-1828341=>
- Figure 2: <https://radiopaedia.org/cases/vertebral-artery-dissection-1>
-