

# Intra-Parietal Hernia formation following Complex Abdominal Wall Reconstruction using Posterior Component Separation and Unilateral Transversus Abdominis Release for Repair of Ventral Wall Hernia

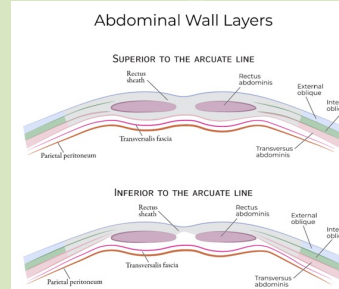
Julian Rupkey, B.S<sup>1</sup>, Julianne Miranda Cribb, M.S<sup>1</sup>, Nura Gouda, D.O<sup>2</sup>, Peter Bamberg, M.D<sup>2</sup>  
1. Drexel University College of Medicine, Philadelphia, PA  
2. Department of General Surgery, Tower Health Reading Hospital, West Reading, PA

## Introduction

Ventral abdominal wall hernia repairs represent a large proportion of surgical cases for general surgeons with a large majority classified as incisional hernias. These arise following use of large surgical incisions often associated with exploratory laparotomy. A rare category of hernia is an intraparietal hernia, where contents protrude between layers of the abdominal wall rather than at the subcutaneous tissue level. For any hernia, bowel contents or fat protrudes through a weakened area of muscular wall. If unable to reduce, these incarcerated hernias may become strangulated if blood supply is compromised necessitating emergent intervention. Ventral hernia defects can become quite large and tension free reapproximation of these defects can be technically challenging. Approaches involve anterior/posterior component separation (ACS/PCS) of the abdominal wall muscles, creation of a retro-rectus plane for mesh, and if indicated, utilization of Transversus Abdominis Release (TAR). A TAR is often used with a PCS and involves releasing the transversus abdominis muscle from its lateral attachments to facilitate greater medialization of the rectus muscles to create a tension free midline fascial closure. Our case report describes a patient with a large ventral wall hernia who underwent repair with PCS & TAR with formation of an intra-parietal hernia on post-op day 3 (POD).

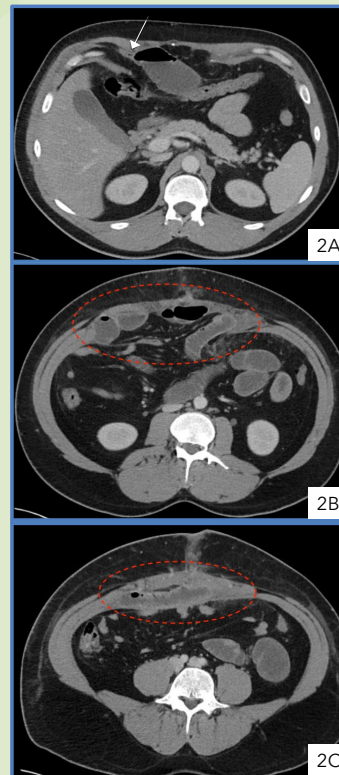
## Case Presentation

- 37-year-old male with a history of laparoscopic robotic hiatal hernia repair in 2016, open sigmoidectomy in 2025. Relevant medical history consists of acute diverticulitis, obesity, and hepatic steatosis.
- Underwent PCS with right sided TAR for repair of 8 cm x 8 cm ventral hernia on 12/2/25.
- Post-op course was complicated by hospital admission in 12/8/25, POD6, with nausea, hiccups, and emesis.
- CT imaging revealed a high-grade small bowel obstruction with a transition point in the right upper abdomen (**Figure 2**).
- On POD7, 12/9/26, patient returned to the operating room for laparoscopic reduction and repair of an incarcerated intraparietal hernia with mesh placement.
- Operation findings significant for breakdown of the previous posterior fascia repair, extending superiorly from the level of the umbilicus. This allowed for loops of small bowel to herniate through the posterior fascia repair migrate superiorly between the abdominal wall muscles to the level of the right subcostal region (**Figure 2**).
- Bowel gently reduced, and edges of posterior fascia were tacked to the rectus abdominis.
- No bowel resection was performed.
- The initial retrorectus mesh was found to be in place. A second 25 cm x 20 cm phasix mesh was placed over the defect in the posterior fascia.
- Following the operation, patient was stable and recovered appropriately with return of bowel function on 12/11/25. Patient tolerated diet advancements, ambulation, and had adequate pain control. Discharged home in stable condition on 12/12.
- Outpatient follow-up, at 3 weeks was significant for lateral abdominal wall discomfort but otherwise recovering well.
- Outpatient follow-up at 2 months, patient reported return to work without difficulty.



**Figure 1.** Diagram demonstrating tissue layers that compose the abdominal wall.

Source: Draw It to Know It (DITKI), <https://ditki.com> (Nursing & Medical Sciences course).



**Figure 2.** Patient CT abdomen/pelvis with contrast imaging. Evidence of high-grade small bowel obstruction indicated by transition point from dilated to collapsed small bowel; demarcated by white arrow (**2A**). Herniation of small bowel through defect highlighted by red dotted circles (**2B,C**).

## Discussion

- This case highlights an uncommon complication following ventral hernia repair utilizing the transversus abdominis release (TAR) technique.
- The atypical presentation of intraparietal hernias can make diagnosis challenging, and often requires a high index of suspicion, especially in patients presenting with persistent or unusual abdominal wall discomfort following complex reconstruction.
- The TAR technique has become increasingly favored for complex ventral hernia repair due to its ability to achieve midline fascial closure with low tension while maintaining favorable recurrence rates. Recent literature reports recurrence rates as low as approximately 2.5% within the first postoperative year.
- This case underscores that even with low recurrence rates, unique and less commonly described complications such as intraparietal hernias may still occur.
- This case emphasizes the importance of careful postoperative monitoring and consideration of atypical hernia subtypes in patients with persistent or localized abdominal wall symptoms after TAR repair.
- Further study is warranted to better characterize risk factors, optimal diagnostic approaches, and management strategies for intraparietal hernias in the context of advanced abdominal wall reconstruction techniques.

## Acknowledgements & References

- We thank Dr. Peter Bamberger, MD, for his clinical management of this case.
- 1) Gandhi, J. A., Gajjar, A. P., Shinde, P. H., & Chaudhari, S. (2024). Posterior Component Separation Technique-Original Transversus Abdominis Release (TAR) Technique. *Journal of abdominal wall surgery* : JAWS, 3, 12542. <https://doi.org/10.3389/jaws.2024.12542>
  - 2) Mehta, Nisarg Y.; Casaubon, Jesse; Benedicto, Ramon. Open mesh repair of interstitial hernia containing small bowel. *International Journal of Abdominal Wall and Hernia Surgery* 2(4):p 149-151, Oct-Dec 2019. | DOI: 10.4103/ijawhs.ijawhs\_11\_19
  - 3) Ivakhov, G. B., Kalinina, A. A., Titkova, S. M., Anurov, M. V., Andriyashkin, A. V., Glagolev, N. S., Burenkov, I. A., & Sazhin, A. V. (2025). Interparietal hernias after posterior component separation. *Hernia : the journal of hernias and abdominal wall surgery*, 30(1), 37. <https://doi.org/10.1007/s10029-025-03548-9>
  - 4) Goda, M. H., Abdelrahim, H. S., Elmaleh, H. M., Amer, A. F., & Ehab Mohammed Ali. (2022). Transversus Abdominis Release Versus Anterior Component Separation in Ventral Abdominal Hernia - A Prospective Comparative Study. *Surgery, Gastroenterology and Oncology (Print)*, 27(3), 198-198. <https://doi.org/10.21614/sgo-460>