

# Evaluating the Role of TNK Use for Minor Stroke Symptoms

McNulty, Jade M., Philadelphia College of Osteopathic Medicine, OMS III

## ABSTRACT

Thrombolytic therapy with Alteplase or Tenecteplase is standard of care for acute ischemic stroke within 4.5 hours of symptom onset, although many presentations are classified as minor (NIHSS  $\leq 5$ ) (Powers et al., 2019). This case describes a 27-year-old woman with minimal neurologic deficit (NIHSS 1) who received Tenecteplase, resulting in rapid symptom resolution and no infarction on follow-up MRI.

Despite the favorable outcome, the role of Tenecteplase in minor stroke remains uncertain given its associated risks and unclear advantage over dual antiplatelet therapy. Further research is needed to guide management in this population.

## INTRODUCTION

Tenecteplase (TNK) is a thrombolytic agent used in the management of acute ischemic stroke, increasingly favored for its longer half-life, which allows for single-bolus administration (Warach, 2021). Current treatment guidelines recommend thrombolysis for eligible patients presenting within 4.5 hours of symptom onset, provided there are no contraindications such as active bleeding, bleeding disorders, recent stroke, or recent intracranial or intraspinal surgery (Bach and Lui, 2023). Despite its benefits, TNK carries a risk of significant adverse effects, most notably bleeding, including intracranial hemorrhage, which occurs in approximately 2% of cases (Rose, 2023).

Recent studies comparing TNK with dual antiplatelet therapy in patients with minor ischemic stroke have demonstrated similar functional outcomes, with a lower risk of bleeding observed in those treated with dual antiplatelet therapy (Jiang, 2025). These findings highlight ongoing uncertainty regarding the optimal management of patients with minor or non-disabling stroke symptoms and underscore the need for further research to better define the role of TNK in this population.

## CLINICAL COURSE & OUTCOME

A 27-year-old female presented with acute onset left-sided facial, arm, and leg numbness consistent with minor stroke.

**On presentation:** NIHSS 1; CT/CTA showed no acute intracranial abnormality.

### Patient Timeline:

**5:30 PM** – Sudden onset left facial, arm, leg numbness

**6:30 PM** – Arrival to ED

**CT/CTA** – No acute intracranial abnormality

**TNK administered** – Within treatment window

**+1 hour** – Symptoms resolved

**Next day MRI** – No evidence of infarction

### Neurological Status:

On Arrival: NIHSS Score 1

Post-TNK: NIHSS Score 0 (resolved)

### Why Tenecteplase?

*Within 4.5-hour treatment window*

*Acute focal neurologic deficit*

*No contraindications to thrombolysis*

*Single bolus administration advantage*

**Key Outcome: Rapid symptom resolution with no radiographic infarction**

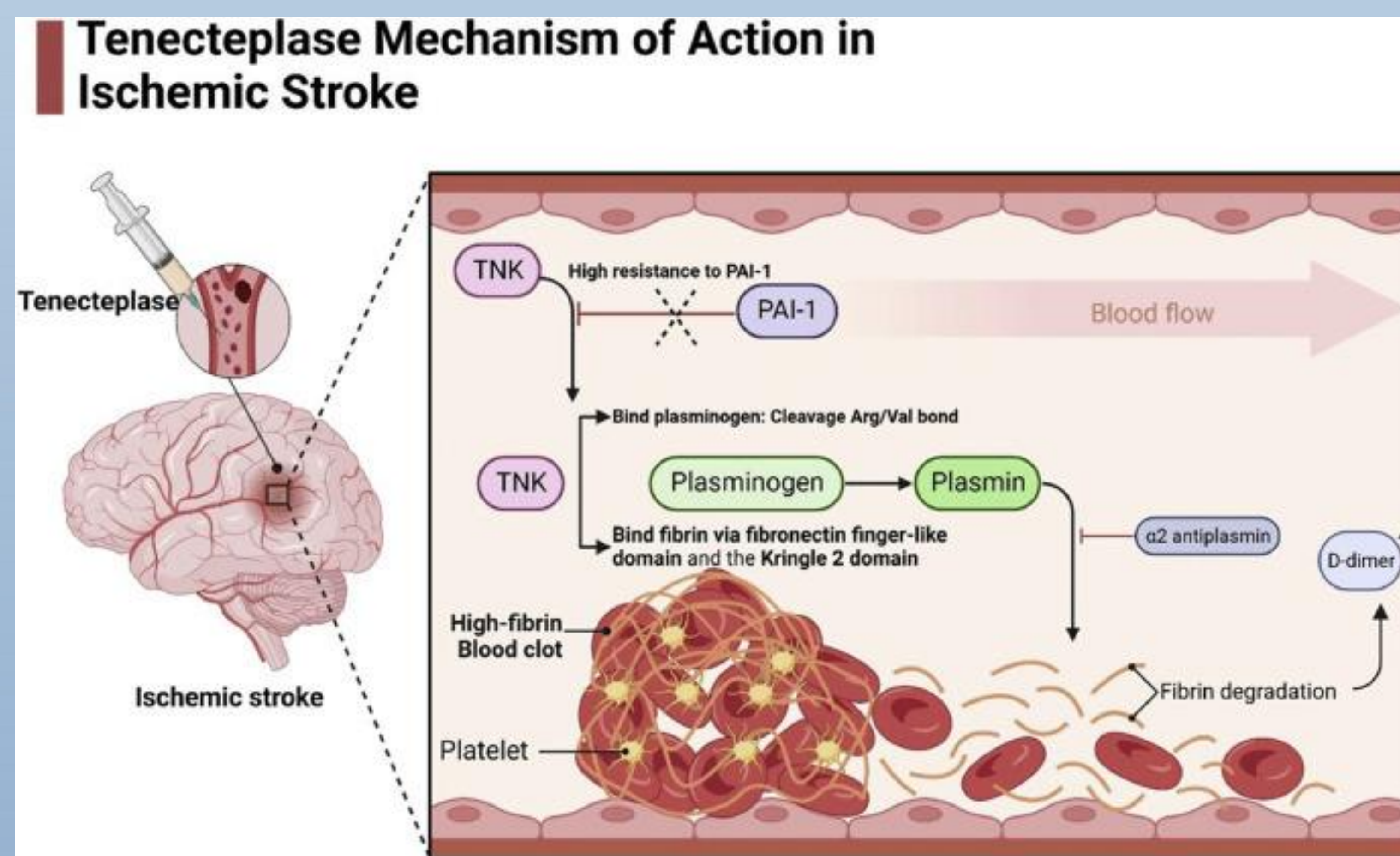


Figure 2. Tenecteplase Mechanism of Action in Acute Ischemic Stroke, Haj Mohamed Ebrahim Ketabforoush

## DISCUSSION

This case highlights the use of Tenecteplase (TNK) in a patient presenting with minor, potentially self-limiting stroke symptoms. Although no adverse events were observed, TNK administration is not without risk and carries the potential for significant complications, most notably intracranial hemorrhage, which contributes to increased morbidity (Rose, 2023).

Dual antiplatelet therapy has emerged as a potential alternative in the management of minor ischemic stroke. Recent comparative studies suggest that TNK may not confer a significant functional benefit in this population and may be associated with increased 90-day mortality compared to dual antiplatelet therapy (Jiang, 2025).

Taken together, this case underscores the ongoing uncertainty in the management of minor stroke and highlights the need for updated clinical guidelines to better define the safest and most effective treatment strategies for these patients.

## REFERENCES

- Haj Mohamad Ebrahim Ketabforoush, et al., (2024) *Optimizing Acute Ischemic Stroke Outcomes: The Role of Tenecteplase Before Mechanical Thrombectomy*, *Clinical Therapeutics*, Vol 46: 11
- Jiang, Xinzhao et al., (2025), *Comparison of the safety and efficacy of dual antiplatelet therapy versus Tenecteplase in patients with minor nondisabling acute ischemic stroke*. *Scientific Reports*. 15;1685
- Powers, W. J. et al. *Guidelines for the early management of patients with acute ischemic stroke: 2019 update to the 2018 guidelines for the early management of acute ischemic stroke: a guideline for healthcare professionals from the American Heart Association/American Stroke Association*, *Stroke* 50
- Bach, Kieu-Tram, Lui, Forshing (2023) *Tenecteplase Statpearls*
- Warach, Steven J., et al (2021) *Tenecteplase Thrombolysis for Acute Ischemic Stroke*. *Stroke*. 13;51
- Shen, Lei et al (2026) *Immediate Brainstem Hemorrhage after Thrombolysis in Ischemic Stroke With Poorly Controlled Hypertension: Insights From Three Clinical Cases*. *Journal Central Nervous System Disease*
- Rose, Deborah et al (2023) *Complications of Intravenous Tenecteplase Versus Alteplase for the Treatment of Acute Ischemic Stroke: A Systematic Review and Meta-Analysis*, *Stroke*
- National Institute of Neurological Disorders and Stroke. (2011). *NIH stroke scale*. U.S. Department of Health and Human Services.

## ACKNOWLEDGEMENTS

*Special thanks to the patient who inspired this case report*