An Osteopathic Approach to Carpal Tunnel Syndrome

David B. Fuller, D.O., F.A.A.O.
Professor
Osteopathic Manipulative Medicine Department, PCOM

Board certified in:
- Neuromusculoskeletal Medicine and Osteopathic Manipulative Medicine
- Family Medicine and OMT
- Integrative Holistic Medicine

#POMA19
#ChooseKnowledge

1

Disclosures

I have no relevant financial relationships or conflicts of interest to disclose.

#POMA19
#ChooseKnowledge

2

Osteopathic Approach

"Acquaint yourselves with all structures by a deep and continued study of anatomy, because on this foundation you must stand or fall."

Dr. A. T. Still

#POMA19
#ChooseKnowledge

3

Osteopathic Approach

- Problem solve with a neuromusculoskeletal model in mind
  - Neurological
  - Fluid
  - Mechanical

#POMA19
#ChooseKnowledge

4

Neurologic Component -Sympathetic and Somatic

- Reduce sympathetic tone to the upper extremity
  - Correct upper thoracic and upper rib dysfunctions
- Correct cervical somatic dysfunction to improve nerve root and brachial plexus function
- Address any "double crush" component at neck, thoracic outlet or shoulder/brachial plexus
- Address any restriction in the interosseous membrane of the forearm
- Reduce any compressive forces on median nerve

#POMA19
#ChooseKnowledge

5

Fluid Component

- Remove myofascial restrictions thereby removing potential sites of additional compression.
  - Cervical
  - Thoracic outlet
  - Upper extremity

#POMA19
#ChooseKnowledge

6

Mechanical

- Increase space within the carpal tunnel
  - Direct fascial release techniques to wrist
  - Utilizing wider proximal wrist flexor tendons to dilate carpal tunnel
  - Correct any ligamentous strain

#POMA19
#ChooseKnowledge

7

Carpal Tunnel Syndrome

- Entrapment neuropathy of the median nerve caused by compression and irritation the nerve as it passes through the carpal tunnel
- Pain and tingling in distribution of median nerve
- Can progress to atrophic changes

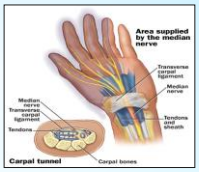

DAVID B FULLER, DO, FAAO

#POMA19
#ChooseKnowledge

8

Symptoms

- Pain and paresthesias in the thumb, index and long fingers
- Aching can spread to forearm, arm, shoulder, and rarely to the neck
- Early pain is transient, later continuous

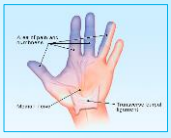

#POMA19
#ChooseKnowledge

9

Symptoms

- Aggravated by provocative activities
- Often occurs while sleeping
- Vague weakness or mild subjective loss of coordination
- Obvious weakness/atrophy is a late presentation

#POMA19
#ChooseKnowledge

10

Differentiating CTS from Cervical Radiculitis

- Study in the journal *Hand Surgery* compared patients who had surgery for cervical spondylosis with those for CTS (after excluding cases of co-morbidity)
- CTS vs. cervical spondylosis
  - Nocturnal paresthesia 84% vs. 10%
  - Hand paresthesia aggravated by hand activity 82% vs. 7%
  - Hand pain 64% vs. 10%
  - Neck Pain 14% vs. 76%

#POMA19
#ChooseKnowledge

11

Physical Exam

- Median nerve sensory deficit
  - Often splitting along the long or ring finger
- Fascial restrictions at the wrist
- Loss of the normal 15-30 degrees of resting ulnar deviation at wrist

#POMA19
#ChooseKnowledge

12

Carpal Tunnel Syndrome

- Provocative testing (3 of my favorites)
  - Tinel test at the carpal tunnel
  - Phalen's test
  - Carpal compression test (Durkin's)
- Muscle wasting
  - Thenar atrophy

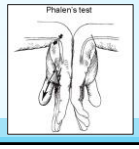

#POMA19
#ChooseKnowledge

13

Median Nerve Supply – Somatic and Sympathetic

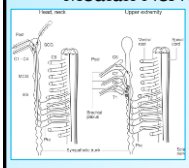

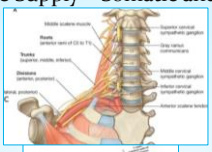

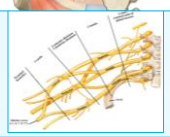

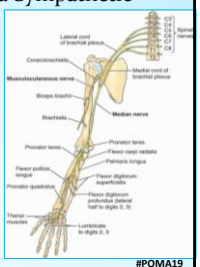

#POMA19
#ChooseKnowledge

14

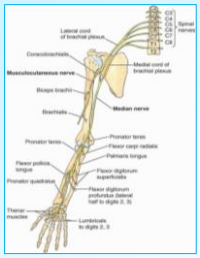

#POMA19
#ChooseKnowledge

15

Importance of Interosseous Membrane in Wrist Dysfunction

- The interosseous membrane plays an important role in wrist mechanics and function/dysfunction
- Treatable with OMT, including LAS and BLT

#POMA19
#ChooseKnowledge

DAVID B. FULLER, DO, FAAO

16

Wrist/Forearm Techniques for Today

- While there are many possible OMM techniques for treating CTS, today we will focus on primarily two
  - **Direct myofascial release (Dr. Sucher)**
  - **LAS technique for the wrist**
- Other options to consider are:
  - Counterstrain to the forearm flexors
  - Still Technique to anterior wrist
  - Muscle energy technique for radial head dysfunctions (pronation/supination)
  - HVLA for wrists articular dysfunctions
  - LAS for forearm/interosseous membrane

#POMA19
#ChooseKnowledge

17

Direct Myofascial Release of Carpal Tunnel – Sucher Technique

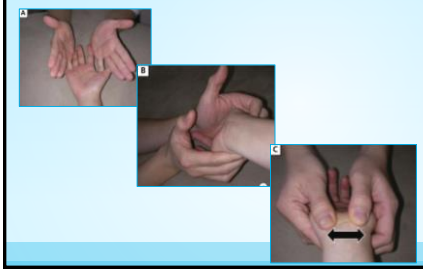



#POMA19
#ChooseKnowledge

18

Home Stretch

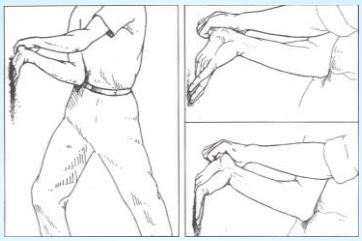

#POMA19
#ChooseKnowledge

19

A ("Still-ish")Ligamentous Articular Strain for CTS

- LAS
  - Disengage
  - Exaggerate
  - Balance
- Still
  - Indirect, then direct
  - With force vector

#POMA19
#ChooseKnowledge

20

From *Ligamentous Articular Strain*, by Speece and Crow

While maintaining all the forces shown in the previous illustration, place the patient's hand in a position of ulnar deviation (shown). If a barrier is encountered, remain there until it releases, then continue in the direction shown.

Step one

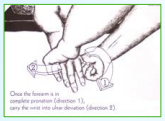

Once the forearm is in complete pronation (direction 1), carry the wrist into ulnar deviation (direction 2).

Step two

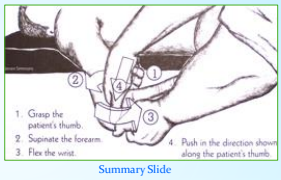

Summary Slide

#POMA19
#ChooseKnowledge

21

Forearm Technique (from *LAS*)

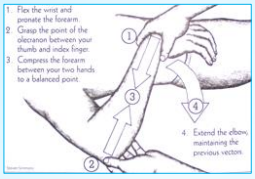

#POMA19
#ChooseKnowledge

22

One Possible CTS OMT Sequence

- Patient seated/supine
  - Thoracic – T1-5
  - Ribs – 1-5,
- Patient supine
  - Cervical
  - Scalenes
  - Thoracic outlet
  - Forearm and wrist

#POMA19
#ChooseKnowledge

23

Osteopathic Approach

- Problem solve with a neuromusculoskeletal model in mind
  - Neurological
  - Fluid
  - Mechanical

#POMA19
#ChooseKnowledge

24

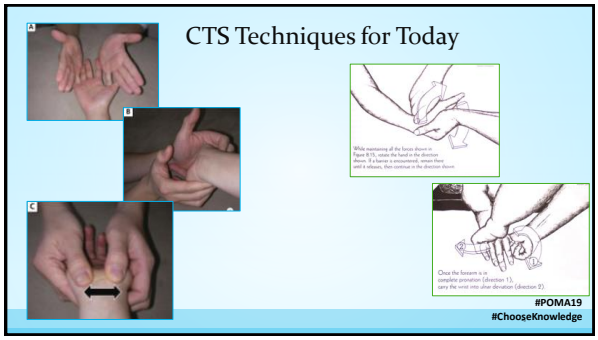
CTS Techniques for Today
A
B
C
While maintaining all the forces shown in Figure 8-15, rotate the hand in the direction shown. If a barrier is encountered, remain there until it releases, then continue in the direction shown.
Once the forearm is in complete pronation (direction 1), carry the wrist into ulnar deviation (direction 2).
#POMA19
#ChooseKnowledge

25