

Basic Diagnosis of Rotator Cuff Tears
and
Differentiating Shoulder
Impingement Syndrome from a
Supraspinatus Tear

STEPHEN PAGE PT, DPT

Disclosure

I have no actual or potential conflict of interest in relation to this program/presentation.

What's The Point?

- ▶ Accurately diagnosing Rotator Cuff Tears (RCT) can be difficult and time consuming
 - ▶ Partial thickness tears
- ▶ Help decide if an MRI is warranted before the plan of care is fully determined
 - ▶ Avoid slowing the process of a patient's recovery
- ▶ RTC (specifically the Supraspinatus) can present similarly to shoulder impingement
 - ▶ Similarities in general presentation and etiology
 - ▶ Location of pain
 - ▶ Pain with shoulder elevation
 - ▶ Pain with sleeping on the symptomatic side
 - ▶ Pain with or without a traumatic event

Objectives (What to Expect)

- ▶ Obtain a basic and brief review of relevant shoulder anatomy
- ▶ Understand key signs and symptoms related to each specific RCT tear
- ▶ Achieve competency in basic and efficient screening/performance of special tests for all 4 tendons of the RCT
- ▶ Understand how to quickly differentiate between a Supraspinatus tear and Shoulder Impingement Syndrome/Subacromial Bursitis

What NOT to Expect

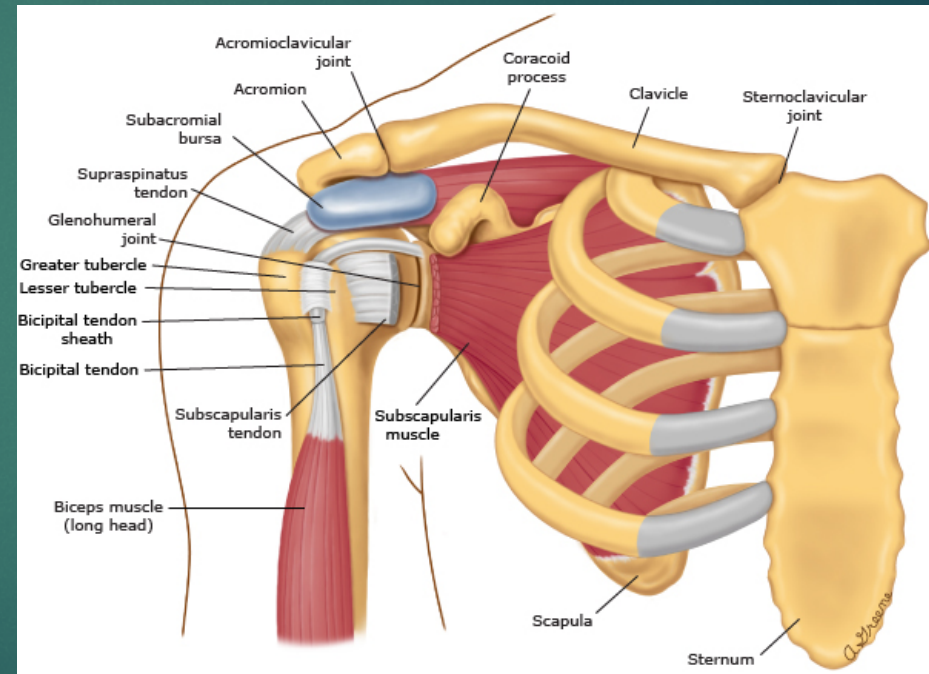
- ▶ This lecture does NOT contain a comprehensive list of special tests for discussed pathologies
 - ▶ Included “best,” “specific,” and “easiest to perform”
- ▶ This lecture is NOT intended to serve as a comprehensive exam of someone with suspected shoulder pathology
- ▶ Treatment of shoulder pathology is NOT discussed in depth in this lecture

Basic Anatomy of the Shoulder

Basic Anatomy of the Shoulder

Structures to highlight Right Anterior Shoulder¹

- ▶ Acromion
- ▶ Supraspinatus tendon
- ▶ Greater tubercle
- ▶ Subscapularis
- ▶ Subacromial bursa

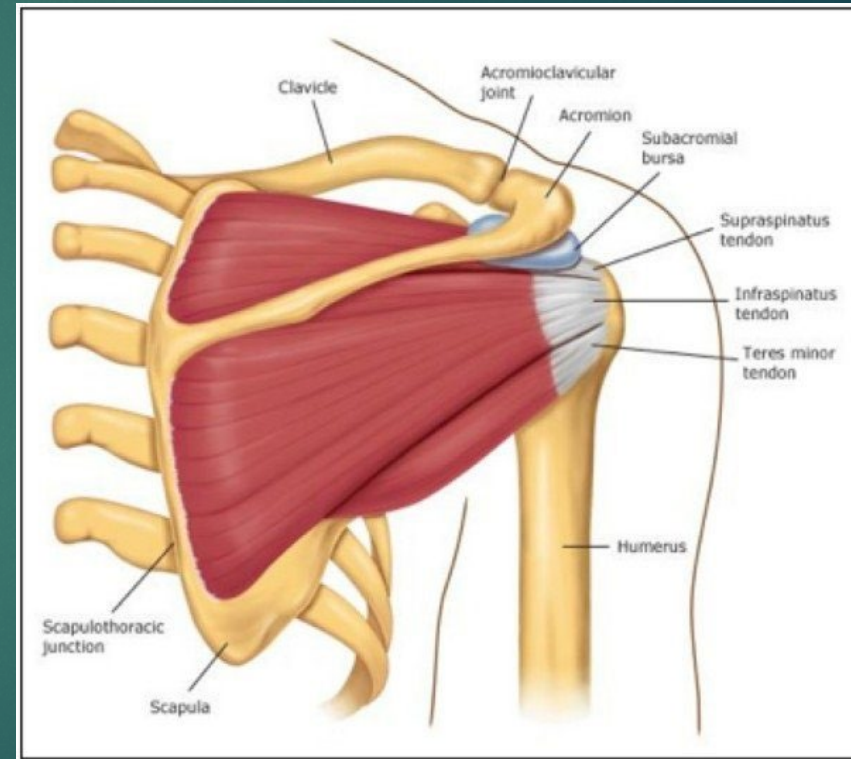


Basic Anatomy of the Shoulder

Structures to highlight

- ▶ Acromion
- ▶ Spine of scapula
- ▶ Supraspinatus
- ▶ Infraspinatus
- ▶ Teres Minor

Right Posterior Shoulder²



Rotator Cuff Tears

Rotator Cuff Tears

- ▶ Common Etiology:
 - ▶ Trauma
 - ▶ Fall on outstretched arm
 - ▶ My experience: Usually a lateral or posterior element to the fall.
 - ▶ Heavy weight lifted/manipulated
 - ▶ Usually in an “odd” position
 - ▶ Age 65 years old or older³
 - ▶ Activities (overhead sport or profession)
 - ▶ Note: Can happen without any trauma
 - ▶ Typically arthritic and/or chronic shoulder impingement syndrome

General Screening for RCT

- ▶ Shrug test
 - ▶ Either a tear, arthritic, or adhesive capsulitis⁴
- ▶ Lateral Jobe Test
 - ▶ Any RCT
 - ▶ Highlights Supraspinatus tears (not specific to them)
- ▶ External Rotation Lag Sign
 - ▶ Likely a large (full thickness) tear present
 - ▶ Highlights ERs (not specific to them)

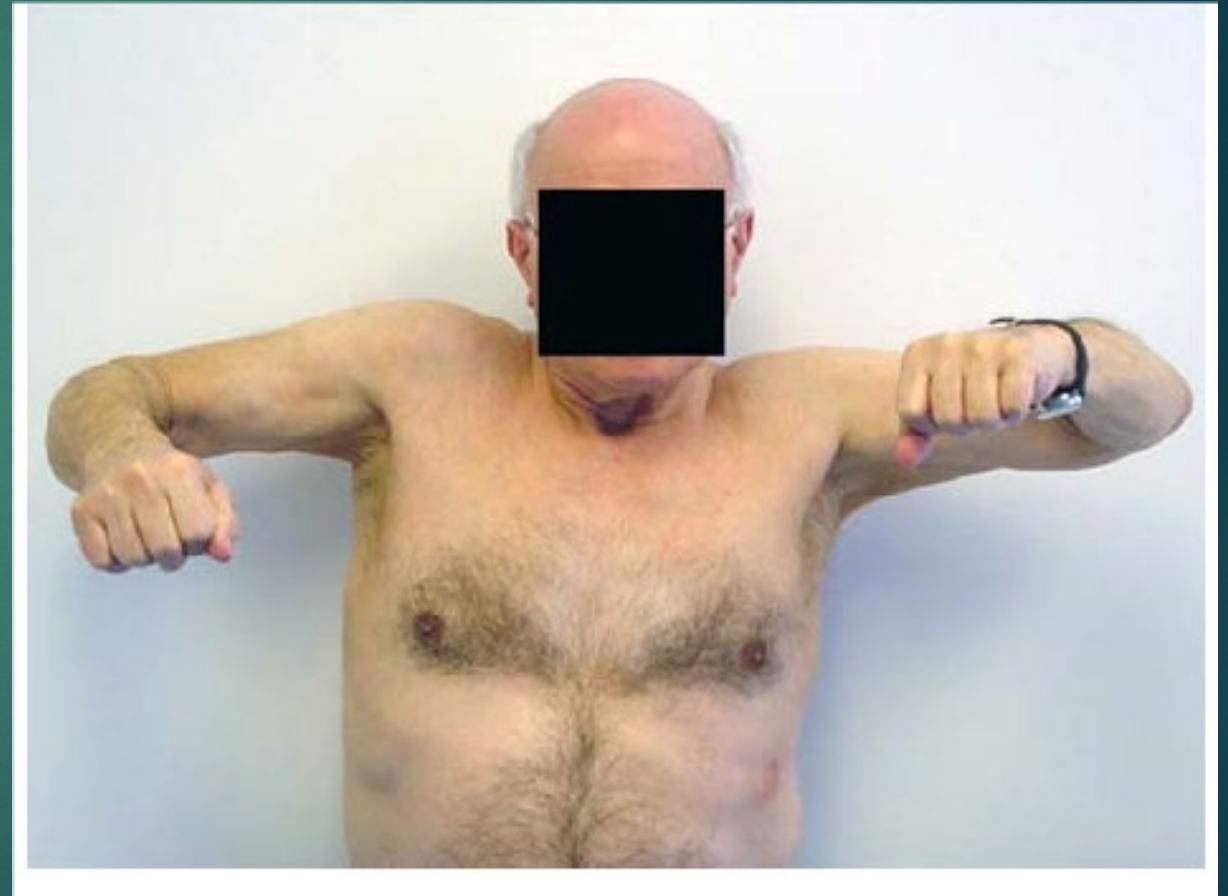

Special Tests for General RCT Screen

Shrug Test⁵

Details:

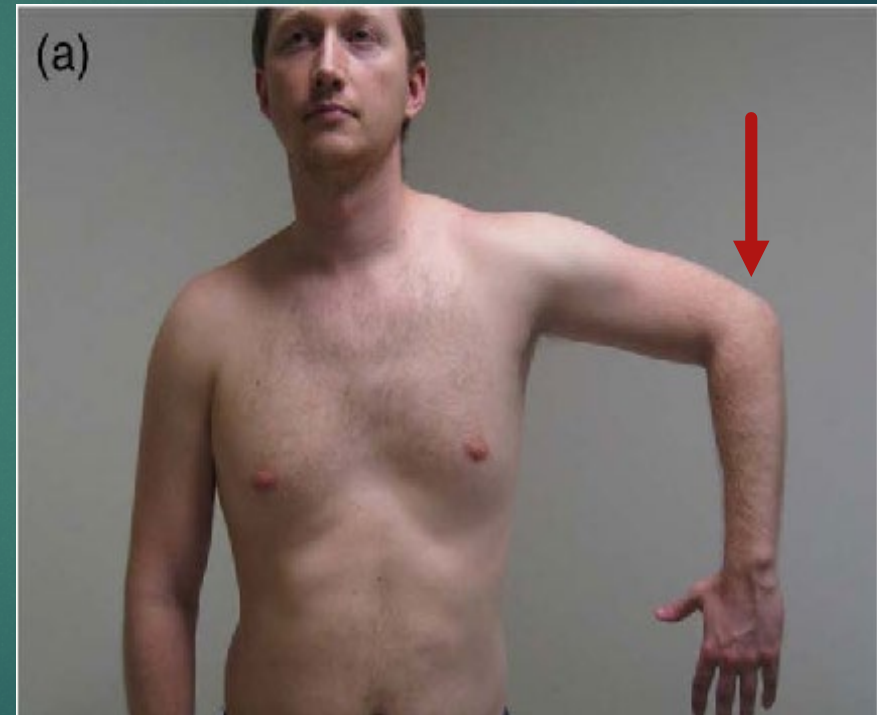
- ▶ Should be done in standing
 - ▶ Can be done in seated
- ▶ Effective in ruling OUT a tear if shrug sign is not present³
- ▶ Ask pt to abd shoulders to 90 degrees in the frontal plane with elbows flexed at 90 degrees and palms down
- ▶ Positive findings: Pt unable to perform or has to elevate shoulder girdle of pathological side
 - ▶ Angle of abd is less in positive findings



Lateral Jobe Test⁶

Details:

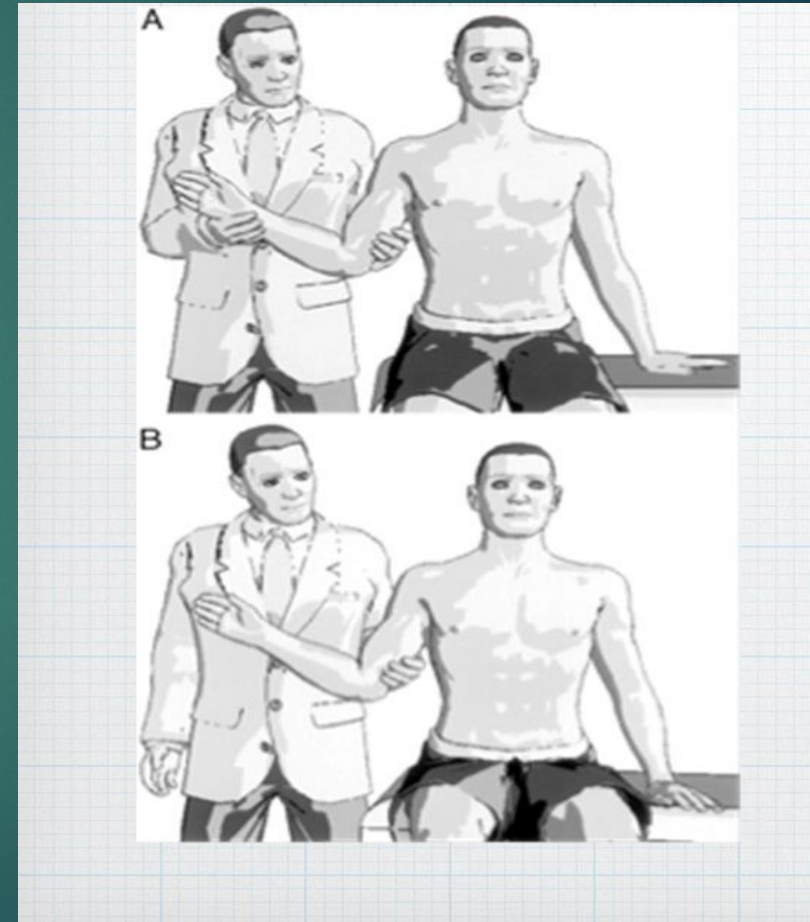
- ▶ Should be done in standing
 - ▶ Can be done in seated
- ▶ Effective for ruling IN and OUT a RCT³
- ▶ Ask pt to abd shoulder to 90 degrees in the frontal plane with IR so that the fingers are pointed towards the floor and thumb is directed medially. Examiner then directs an inferior force on the elbow
- ▶ Positive findings: pain, weakness, and/or inability to perform test
- ▶ Compare with unaffected side



External Rotation Lag Sign⁷

Details:


- ▶ Done in seated
 - ▶ Avoid if patient has significant anterior instability
- ▶ Effective for ruling IN a RCT³
- ▶ Examiner is behind pt and holds patient's elbow and wrist. Examiner abd shoulder 20 degrees in scaption, and ER shoulder to end of range. Ask pt to hold this position when examiner releases the wrist (not the elbow)
- ▶ Positive findings: Pt unable to hold this position
 - ▶ Suspect tear of infraspinatus/teres minor
- ▶ Compare to unaffected side if needed



Supraspinatus Tear

Specific Things To Consider

- ▶ Palpable tenderness: muscle vs insertion point
- ▶ AGE: > 65 years old
- ▶ History: overhead activities (sport or profession)
- ▶ Trauma:
 - ▶ Fall on outstretched arm (lateral or posterior direction)
 - ▶ Lifting something heavy overhead
- ▶ Location of pain
- ▶ Additional tests:
 - ▶ Empty Can test
 - ▶ Do a variation*
 - ▶ Drop Arm Test
 - ▶ Do a variation



Additional Tests For Supraspinatus Tear

Empty Can Test⁸

Details:

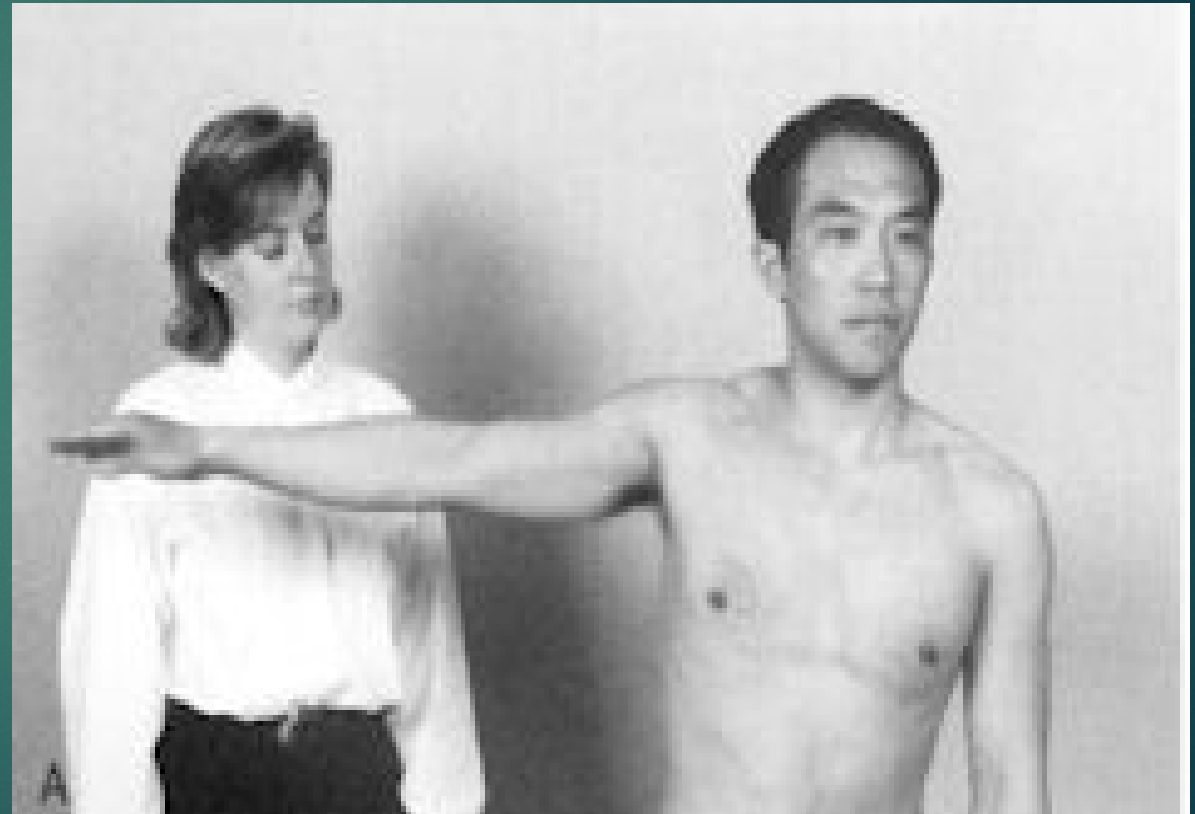- ▶ Patient should be standing
 - ▶ Can be done in seated
- ▶ Ask pt to abd shoulder to 90 degrees in scaption with full IR of shoulder and pronation of the wrist. Stabilize the shoulder and add an inferior force at the distal forearm
- ▶ Positive findings: pain, weakness, and/or inability to perform test
- ▶ Helpful variations*
- ▶ Compare to unaffected side if needed



Drop Arm Test⁹

Details:


- ▶ Should be done in standing
 - ▶ Can be done in seated
- ▶ Ask pt to abd their shoulder to 90 degrees in the frontal plane with the elbow completely extended and hold the position
- ▶ Positive findings: unable to hold arm at 90 degrees
 - ▶ Watch for shoulder elevation
- ▶ Variations
 - ▶ AROM (ratchet like motion), palm up vs palm down
- ▶ Compare to unaffected side if needed



Infraspinatus Tear

Specific Things To Consider

- ▶ Age: > 65 years old
- ▶ Location of pain (palpation)
- ▶ Mechanism of Injury
 - ▶ Tenderness to palpation
 - ▶ Fall on outstretched arm
 - ▶ Pulling injury
 - ▶ Overhead injury
 - ▶ Deceleration injury
- ▶ Additional Tests:
 - ▶ Infraspinatus test
 - ▶ AROM vs resistance
 - ▶ Tested in different ranges of elevation
 - ▶ Look for shoulder retraction



Additional Tests For Infraspinatus Tear

Infraspinatus Test¹⁰

Details:

- ▶ Can be done in seated
- ▶ Part 1: Ask pt to perform ER of both shoulders with elbows by the pts side and flexed to 90 degrees, thumb facing superior
- ▶ Part 2: If pt is able to perform part one, have the pt keep their elbow by their side and flexed 90 degrees (thumb still up). IR 45 degrees and then resist ER from there
- ▶ Positive findings: unable, decreased AROM, weakness, or pain
- ▶ Variations:
 - ▶ Can do with slight shoulder elevation
- ▶ Compare to unaffected side if needed



Teres Minor Tear

Teres Minor Tear

- ▶ Similar to Infraspinatus
- ▶ Additional Tests:
 - ▶ Horn Blower's Test



Additional Tests For Teres Minor Tear

Hornblower's Test¹¹

Details:

- ▶ Can be done in seated
- ▶ In scaption, have the pt abd the shoulder to 90 degrees and flex the elbow to 90 degrees. Resist ER in this position
- ▶ Positive findings: weakness or pain
- ▶ Variation
 - ▶ Can add some IR to the starting position of the test
- ▶ Compare to the unaffected side if needed



Subscapularis Tear

Specific Things To Consider¹¹

- ▶ Age: > 40
- ▶ History of an anterior shoulder dislocation
- ▶ Difficulty with carrying certain objects in front of the body
 - ▶ Holding box with two hands (inward motion)
- ▶ Location of pain
 - ▶ May seem like long head of biceps pain
- ▶ Weakness or pain with IR
 - ▶ Difficulty turning a steering wheel

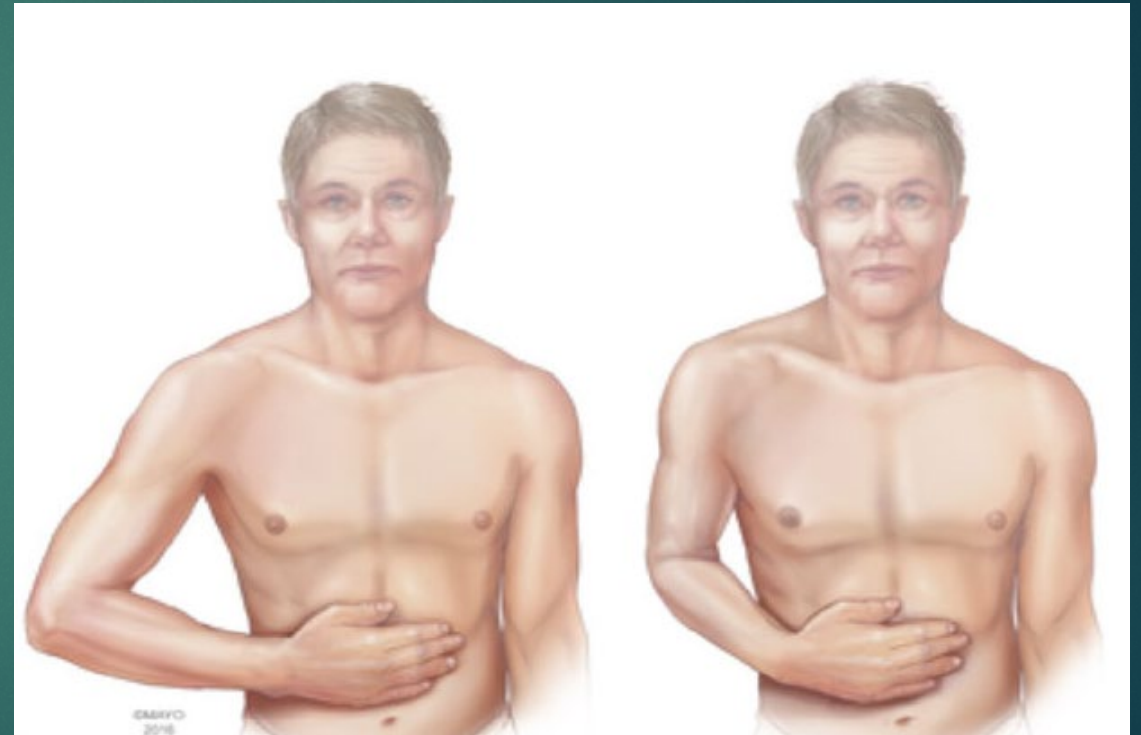


Additional Tests for Supraspinatus

Belly Press Test¹²

Details:

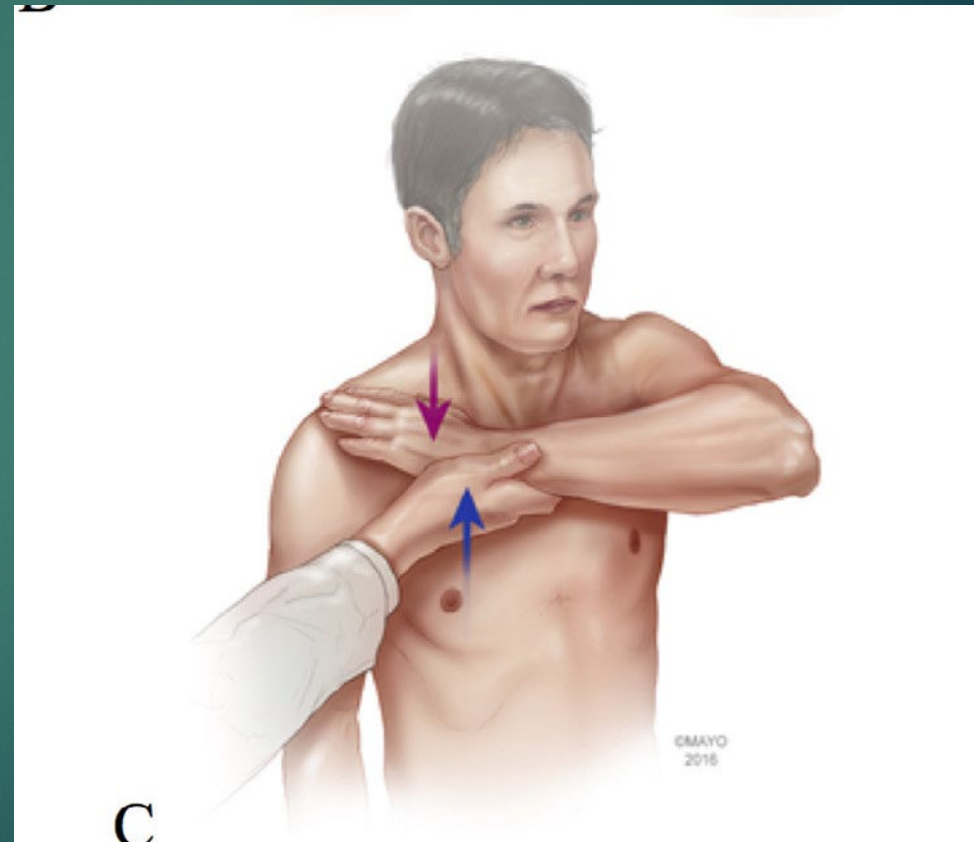
- ▶ Done in sitting
- ▶ Ask pt to put their hand flat on their belly (sit with good posture). Instruct pt to press into their belly while keeping the elbow in the sagittal plane (IR shoulder)
- ▶ Positive findings: elbow drops behind the body into shoulder extension
- ▶ Compare to unaffected side if needed



Bear Hug Test¹²

Details:

- ▶ Can be done in seated
- ▶ Ask pt to place hand of pathological extremity on the unaffected shoulder (elbow flexed and fingers extended). Examiner tries to pull hand off of the shoulder (upward motion)
- ▶ Positive findings: unable to maintain hand on shoulder
- ▶ Compare to unaffected side if needed




Golden Nuggets

- ▶ 3 tests can help confirm presence of a RCT
 - ▶ Shrug (rules OUT a tear)
 - ▶ Especially if <65 years old and no capsular pattern for adhesive capsulitis
 - ▶ Lateral Jobe (rules IN and OUT a tear)
 - ▶ Excellent test
 - ▶ Highlights supraspinatus, but not specific to it
 - ▶ External Rotation Lag sign (rules IN a tear)
 - ▶ Large tears
 - ▶ Highlights ERs but not specific to them

Golden Nuggets

- ▶ DON'T forget to ask for past history (overhead sports or profession)
- ▶ Fall on an out stretched arm
 - ▶ Look for lateral or posterior element to the fall
- ▶ DON'T forget about location of pain (can palpate)
 - ▶ Suprapinatus
 - ▶ Infraspinatus/Teres Minor
 - ▶ Subscapularis



Shoulder Impingement and Differentiating from a Supraspinatus tear

Shoulder Impingement

- ▶ What is it?
 - ▶ When structures between the head of the humerus and the acromion impact during shoulder elevation in an irritative nature
 - ▶ Subacromial bursitis
 - ▶ Supraspinatus
 - ▶ Infraspinatus
 - ▶ SLAP Lesion
 - ▶ Arthritis (bone on bone)
 - ▶ Normally with presence of full thickness supraspinatus tear
 - ▶ Tendinitis/swelling

Shoulder Impingement

- ▶ What causes it?
 - ▶ Scapular dyskinesis
 - ▶ Anatomy
 - ▶ Acute injury to RC tendons
 - ▶ RCT
 - ▶ Posture
 - ▶ Repetitive activities
 - ▶ Weakness

Shoulder Impingement

- ▶ What's the Problem?
 - ▶ Tear (partial or full) of the Supraspinatus often causes impingement
 - ▶ **Tests for impingement can be positive with a Supraspinatus tear**
 - ▶ Impingement that involves the Supraspinatus can cause similar symptoms of a Supraspinatus tear
 - ▶ Same location of pain
 - ▶ Many of the same motions will cause the same pain
 - ▶ You DON'T want to diagnose shoulder impingement and miss the partial thickness Supraspinatus tear
 - ▶ You DON'T want to diagnose a partial thickness Supraspinatus tear when it's only impingement

Shoulder Impingement

- ▶ What do we do about it?
 - ▶ Look for a painful arc in shoulder abd (60-120 degrees)
 - ▶ Test both passively and actively
 - ▶ Passive: If shoulder impingement is not present and a tear is, this should NOT be painful
 - ▶ Active: IF RCT is present, this should be painful before and after painful arc (absence of a distinct painful arc)
 - ▶ If patient is <65 years old:
 - ▶ Do the shrug test
 - ▶ Do the Empty Can test BELOW the painful arc
 - ▶ Do Lateral External Rotation Lag Test
 - ▶ Does not cause impingement
 - ▶ Do variation of drop arm test (palm up)

Shoulder Impingement

- ▶ What do we do about it?
 - ▶ Does the pain come and go?
 - ▶ Was the event traumatic?
 - ▶ <65 years old vs >65 years old
 - ▶ Does the patient complain of weakness?
 - ▶ Pain and function impairment?
 - ▶ ***Remember the Lateral Jobe Test!!!***
 - ▶ ***Excellent for ruling IN and OUT***

Sources

1. Picture for Anatomy of anterior shoulder: Official reprint from UpToDate® www.uptodate.com© 2020 UpToDate, Inc. and/or its affiliates
2. Picture for Anatomy of posterior shoulder: https://www.researchgate.net/figure/Rotator-cuff-anatomy-posterior_fig2_38053101
3. Myer CA, Hegedus EJ, Tarara DT, *et al.* A user's guide to performance of the best shoulder physical examination tests. *British Journal of Sports Medicine* 2013;**47**:903-907.
4. Hegedus Eric, Medbridge lecture 2017 "Evidence-Based Examination of the Shoulder."
5. Shrug test picture from https://www.researchgate.net/figure/A-shrug-sign-was-considered-positive-if-the-patient-had-to-elevate-the-shoulder-girdle_fig1_5314426
6. Lateral Jobe test picture from <https://www.semanticscholar.org/paper/A-user's-guide-to-performance-of-the-best-shoulder-Myer-Hegedus/bed71e55787a4d5b70bd2ee318e2bbccbcf6aa7e/figure/6>
7. External Lag Sign picture from <https://slideplayer.com/slide/3430664/>
8. Empty Can picture from <https://musculoskeletalkey.com/shoulder-9/>

Sources

9. Drop Arm Test picture from <https://allcarept.com/blog/is-a-rotator-cuff-tear-really-curable-without-surgery/drop-arm-test/>

10. Infraspinatus Test picture from <https://www.massagetherapy.com/articles/shoulder-series-1-infraspinatus-tendinitis>

11. Lee, Julia, et al. “Subscapularis Tears: Hidden and Forgotten No More.” *JSES Open Access*, vol. 2, no. 1, 2018, pp. 74–83., doi:10.1016/j.jses.2017.11.006.

12. Belly Press Test Picture from https://www.researchgate.net/figure/Subscapularis-physical-examination-maneuvers-A-Lift-off-test-B-Bellypress-test-C_fig1_323500220



Questions?